

Outcome of Anatomic Transphyseal ACL Reconstruction in Juvenile Patients with Open Physes

INTRODUCTION

Anterior cruciate ligament (ACL) injuries are occurring with increasing frequency in skeletally immature patients, as there are more children participating in high-risk sports. Proper diagnosis and timely recognition of these injuries are necessary for appropriate treatment and prevention of future meniscal or chondral injuries.

Previous studies have reported safe and effective results of transphyseal ACL reconstruction in skeletally immature patients. However, the majority of these studies have been in Tanner stage 3 to 5 patients with closing physes.

The purpose of this study was to determine the outcome of all-arthroscopic transphyseal anatomic single-bundle ACL reconstruction with a soft tissue graft in Tanner stage 1 and 2 patients at a minimum of 2 years after surgery.

METHODS

Between 2007 and 2008, 16 prepubescent patients underwent ACL reconstruction using soft tissue grafts. All patients were Tanner stage 1 and 2. Outcomes were assessed at a minimum of 2 years after surgery and included limb alignment, limb length, instrumented testing with the KT-1000 arthrometer, and International Knee Documentation Committee (IKDC) score.

RESULTS

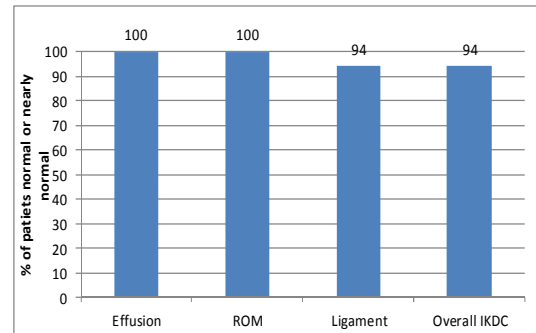
Mean age at the time of surgery was 12 years (range, 8-14 years). There were 12 boys (75%) and 4 girls (25%).

The principal causes of injury were soccer (25%), rugby (12.5%), playground accident (12.5%), motorcycle accident (12.5%), and other sports (38%)

Graft choices included the following: living donor-related hamstring tendon allograft (n = 14), hamstring tendon autograft (n = 1), and fresh-frozen allograft (n = 1).

At 2 years after surgery, all patients had returned to strenuous activities, and normal or nearly normal overall IKDC score was documented in 94% of patients.

The percentage of patients with normal or nearly normal IKDC grading at 2 years is shown here



Mean IKDC subjective score was 96 (range, 84-100). All patients had a stable knee postoperatively. Eleven patients had a negative Lachman test result, and 14 had a negative pivot-shift test result. The remainder had grade 1 Lachman and pivot-shift test findings, respectively.

On single-legged hop testing, 81% (13/16) of patients were able to hop .90% of the distance of the opposite knee. There were no patients with an ACL graft rupture, nor were there any patients with a contralateral ACL injury at the 2-year review.

There were no cases of limb malalignment or growth arrest.

CONCLUSIONS

The treatment of intrasubstance ACL ruptures in children remains controversial. Nonoperative treatment of these injuries until physeal closure in this age group of patients is fraught with difficulty. Despite appropriate education and counseling regarding living within the envelope of stability, compliance remains an issue with children. Previous studies have shown that nonoperative treatment leads to instability, meniscal injury, and arthrosis.

We present a case series of transphyseal anatomic single-bundle ACL reconstruction in Tanner stage 1 and 2 patients at a minimum of 2 years after surgery. Excellent clinical outcomes were obtained with high levels of return to desired activities. Importantly, no growth disturbances were seen in this series of patients.

Catherine Hui, MD, FRCSC,
Justin Roe, MBBS, FRACS,
Duncan Ferguson, MBChB, FRACS,
Alison Waller, BAppSci (Physio),
Lucy Salmon, PhD,
Leo Pinczewski MBBS, FRACS

Presented at:

*Australian and New Zealand Combined Orthopaedic Association Annual Meeting
New Zealand October 2011

* American Academy of Orthopaedic Surgeons Annual Meeting,
San Diego, February 2011
* AOSSM Specialty Day,
San Diego, February 2011

Published
American Journal of Sports Medicine
(in press 2012)



