

Revision ACL reconstruction after use of the LARS ligament. A case series.

Henry Bourke
Con Glezos
Lucy Salmon
Alison Waller
Justin Roe
Leo Pinczewski

Presented at:
Australian Knee Society Annual Meeting,
New Zealand October 2011.
ACL Study Group, Jackson Hole,
USA, February 2012



INTRODUCTION

The Ligament Augmentation Reconstruction System (LARS. Surgical Implants and Devices, Arc-sur-Tille, France) is a synthetic non-absorbable augmentation device made of polyethylene terephthalate (PET). It has rapidly gained popularity in Australia with 982 used in 2009 and 1050 in 8 months in 2010 according to the manufacturers website. Whilst autograft use in Anterior cruciate ligament (ACL) reconstruction has demonstrated excellent clinical results, little has been published to support the use of artificial ligaments. Poor patient outcomes associated with graft failure, tunnel osteolysis, foreign body synovitis and premature arthritis are among the reasons that artificial ligaments were abandoned over two decades ago. Adverse reactions similar to those seen with previous PET ligaments are denied by the manufacturing company and the surgeons who use it.

RESULTS

We report a case series of 6 patients who attended to our clinic for revision of failed LARS ACL reconstruction. In 5 patients single stage revision was possible but in 2 patients a 2 staged procedure was required. There were 4 males and 2 females, mean age 27 years (range 21-36). The cases are summarized in Table 1.

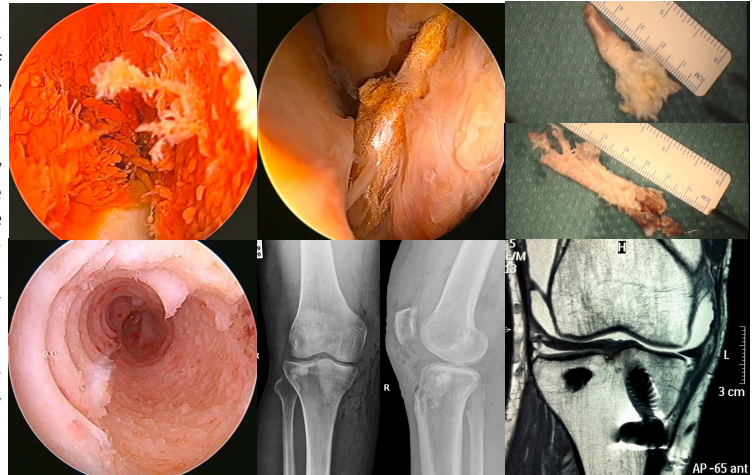
Case no	LARS Survival (months)	Age at revision	Reason for Revision	Widespread cartilage softening
1	8	29	Anterior knee pain, unable to run	No
2	12	33	Pain and swelling	Yes
3	16	21	Stiffness	No
4	17	22	Instability	No
5	19	21	Swelling	Yes
6	24	36	Pain, swelling and disability	No

One 33 year old male (case number 2) demonstrated significant synovitis which is further demonstrated in the figures 1-6. A complete synovectomy was performed and histopathological analysis as follows.

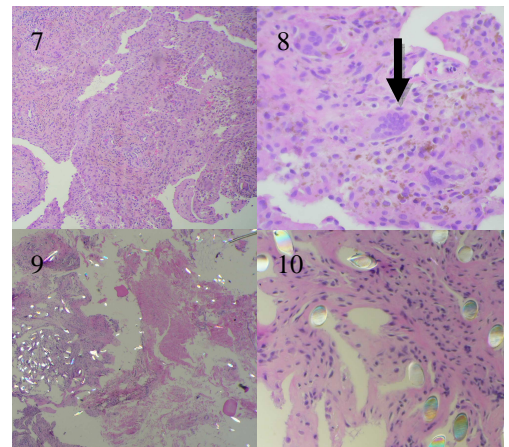
HISTOPATHOLOGICAL ANALYSIS

Macroscopically the frank haemarthrosis and villous synovitis was suggestive of diffuse pigmented villonodular synovitis. On light microscopy, marked haemosiderotic surface synoviocyte hypertrophy and hyperplasia was seen. Within the subsynovial fibroadipose tissue, a degree of expansion by mononuclear multinucleated giant cells was seen (Figures 7 & 8) resembling pigmented villonodular synovitis. Areas of fibroconnective tissue were noted to exhibit prominent

muroid degenerative change. There was no evidence of malignancy. Polarisation light microscopy confirmed abundant brightly polarisable foreign material present throughout, in association with a chronic mononuclear infiltrate (Figures 9 & 10). An acute inflammatory infiltrate as would be expected in sepsis was not seen. The findings were consistent with a haemosiderotic synovitis in a setting of chronic tissue reaction to foreign material (LARS ligament).



Figures 1-3: Severe widespread synovitis with visible PET debris synovectomy (1); Visible LARS fraying with distinct absence of complete fibrovascular ingrowth (2); En-bloc LARS ligament retrieval (3). Figures 4-6: Femoral tunnel highlighting distinctly absent osseous ingrowth about the LARS ligament while osseous ingrowth about the titanium interference screw is complete (4); Bone grafted tunnels on xray and calcium phosphate cement supporting the healed lateral tibial plateau fracture (5); A large effusion on magnetic resonance imaging (6).



Figures 7 & 8: Supra-patella Pouch Synovial Biopsy demonstrating surface villous synovial hyperplasia and hypertrophy with the presence of multiple multinucleated giant cells (arrow). Figures 9 & 10: demonstrating widespread PET wear particles with surrounding chronic inflammatory reaction.

CONCLUSION

Given the demonstrated foreign body synovitic reaction to the LARS ligament and initiation of an iatrogenic degenerative process, we assert the LARS device, like its artificial graft predecessors, should be used with great caution, if at all, for treatment of ruptures of the ACL, particularly in young healthy patients.